


Chapter 1.

Rhinoplasty Lecture - Twisted Nose

The Severely Twisted Nose



29TH ANNUAL SYMPOSIUM

Advances in Aesthetic Plastic Surgery:
The Cutting Edge VII

The Most Advanced and Comprehensive
Aesthetic Plastic Surgery Symposium to Date

November 13-17, 2008
The Waldorf Astor New York

Guest Panelists:
Sherrell Aston, MD, FACS
Thomas C. Rees, MD, FACS
Daniel G. Becker, MD, FACS
Richard L. Galt, MD, FACS

Daniel G. Becker MD
Clinical Associate Professor
Division of Facial Plastic & Reconstructive Surgery
Dept of Otolaryngology-Head & Neck Surgery
University of Pennsylvania & University of Virginia

Dr. Becker was a featured Guest Speaker at the 29th Annual Symposium in New York City, Advances in Aesthetic Plastic Surgery: The Cutting Edge 7. He was the invited speaker in this New York City Rhinoplasty Course. The lecture that he gave on the subject of "The Complex and Severely Twisted Nose" has been transcribed and can be found here.


The Severely Twisted Nose

Thank you, Dr. Tabbal, for that kind introduction. I would also like to thank Dr. Sherrell Aston and Dr. Thomas Rees for their kind invitation to this wonderful symposium, the 29th Annual Symposium here in New York City, Advances in Aesthetic Plastic Surgery: The Cutting Edge 7. It is nice to be back here again at this wonderful conference. You have put together an outstanding rhinoplasty panel – Dr. Nicholas Tabbal from New York City, Dr. Leinhardt from New York City, Dr. Dean Toriumi from Chicago, Dr. Jack Gunter from Dallas, Texas, Dr. Ronald Gruber from Stanford in Palo Alto, California and Dr. Tebbetts from Houston, Texas. I agree with your brochure, that this is “amongst the most advanced and comprehensive aesthetic plastic surgery symposiums to date.”

As many of you know, I trained with Dr. M. Eugene Tardy and Dr. Toriumi in Chicago many years ago, and it is nice to be here in New York City at this Rhinoplasty Conference with my mentor, colleague and friend. I also have gotten to know some of the other panelists over the years, and I look forward to getting to know the rest. And of course I see some familiar faces in the audience. In any case, it is a pleasure to be here in New York City in November. New York City is just a wonderful place to be, and this is a wonderful time of year. I am privileged to be here, talking about Rhinoplasty in New York City.

Chapter 2.

Rhinoplasty Lecture - Annual Symposium

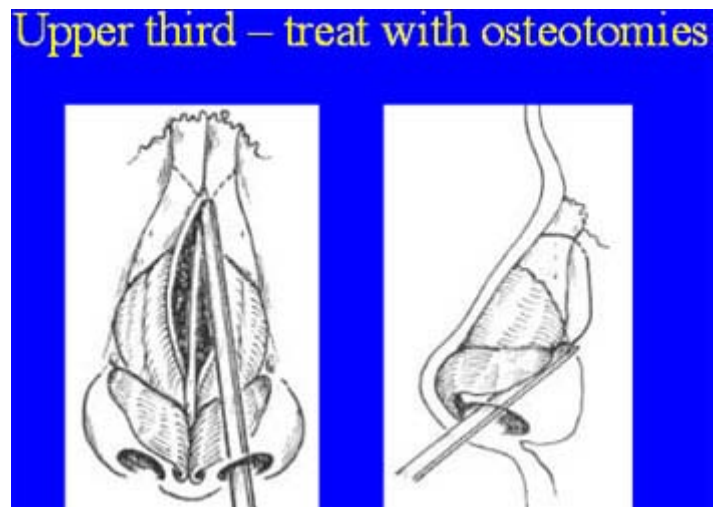


I have been assigned a number of lectures today, and I hope that I am able to provide you with some practical information that you will find useful in your own practice. In this lecture, I am going to speak about the complex and the severely twisted nose.

You can think of the nose, of course, as having an upper, middle and lower thirds, and the nose can be severely deviated in all three portions, and we will talk about those. We will also talk about the cleft lip nasal deformity. The cleft lip nasal deformity is a complicated deviation with multiple component parts. This nasal deformity provides a useful teaching opportunity because, even though it is complex, it is anatomically a predictable deviation. The cleft lip nasal deformity is a good starting point for consideration of complex nasal deviations. We will also discuss other complex deviations, and as with all rhinoplasty they require careful anatomic preoperative nasal analysis. Of course, in all cases, precise anatomic diagnosis is the critical first step for successful treatment. Breaking down the anatomic reasons for the deviation into their component parts allows methodical treatment.

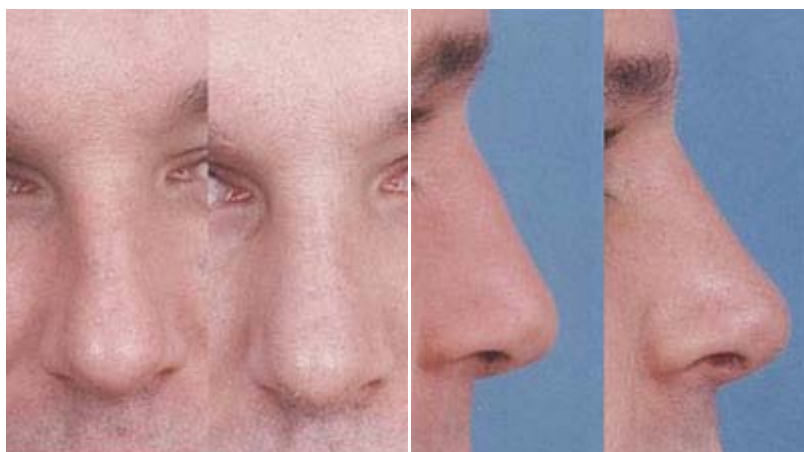Chapter 3.

Rhinoplasty Lecture - Upper Third



So let's start with the upper third. Now, of course, the upper third is bony; it is comprised of the nasal bones and the contribution of the maxilla to the nasal pyramid. And so, when the upper third of the nose is twisted, the treatment is to perform osteotomies, to cut the nasal bones. I will typically use medial and lateral osteotomies.

Sometimes intermediate osteotomies are necessary too. Essentially, you have to diagnose where the bones are twisted. If the nasal bones are shifted off of the midline, then medial and lateral osteotomies will suffice. However, if there is an inherent deviation of the nasal bones, these locations must be identified, and the bone must be cut in these locations – intermediate osteotomies – to allow you to straighten the nasal bone. Here is a patient whose primary request was simply to straighten his nose, and the only thing we did in his surgery was to do medial, intermediate and lateral osteotomies. The only reason his nose was twisted was due to his twisted nasal bones. In this patient, medial, intermediate and lateral osteotomies were required to straighten his nose. No other changes were made to this patient's nose.



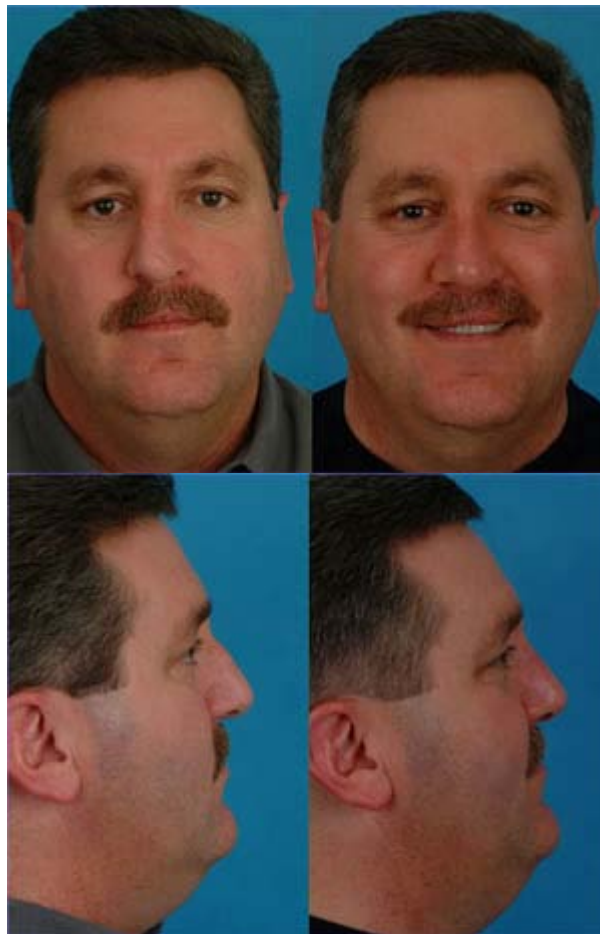When you are fixing a twist of the nose that is caused by the upper or bony portion of the nose, you need to be sure that the deviated bony septum is also straightened. The septum, of course, is on the inside, and if it is twisted you can straighten the outside part of the nose all you want, but if you don't fix and straighten the underlying support structure, then after surgery the nasal bones will just shift back to where they were and the correction will be temporary. There is an instrument that I like to use called a Sayer elevator, and in the situation

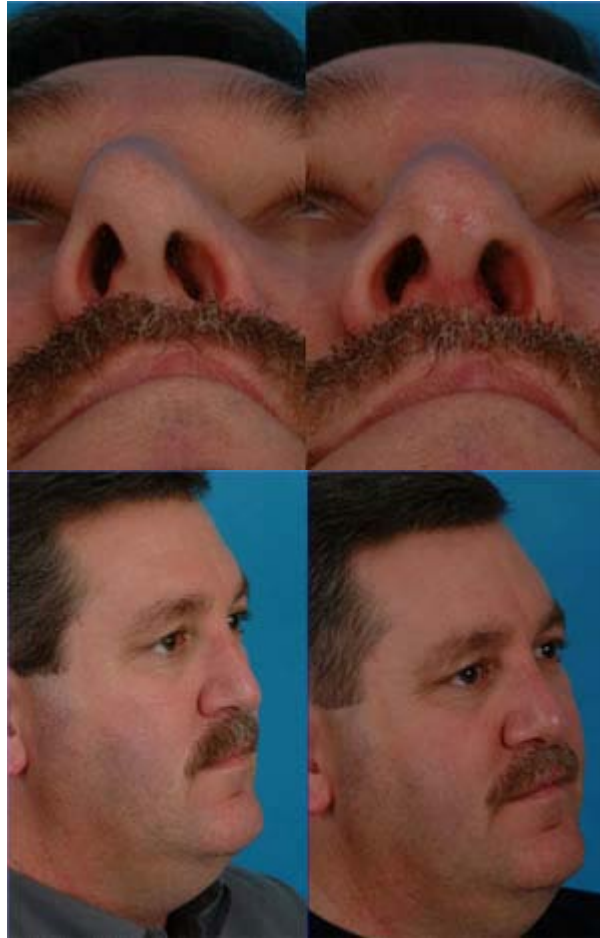that I have just described, I will place the Sayer elevator intranasally and I will fracture the deviated nasal septum in the appropriate location, in that bony portion. That completes my thoughts on the upper or bony third of the nose. I do want to reiterate a take-home point, that you need to carefully analyze the nose to assess if you will need to do more than a medial and lateral osteotomy. Sometimes you need what intermediate osteotomies as well.

Chapter 4.

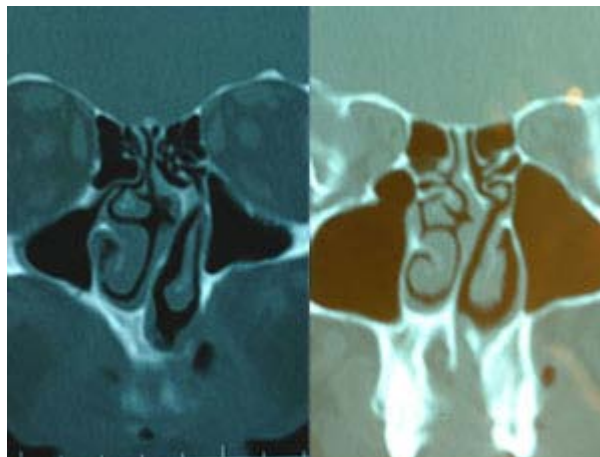
Rhinoplasty Lecture - Cleft Lip Nasal Deformity

Now let's shift to a more complex deviation. Here is a patient who has a cleft lip nasal deformity. He had a cleft lip repaired when he was a child, but he still has a problem with his nose, and it is a very characteristic sort of problem, a "classic" cleft lip nasal deformity. You can see his before and his after picture here from the front. Also he had a nasal bump and a bit of a droopy nose, and we addressed those things too. The bottom view also shows the twist and how we were really able to get a wonderful improvement in the twist of his nose. This oblique view also shows aesthetically the nice improvement that was made.





When you look at his CAT scans you can see that the inside of his nose also is a bit of a jumble.

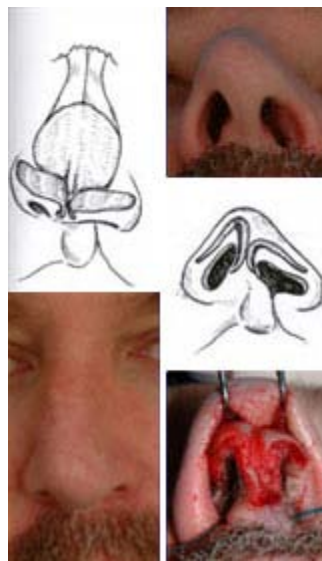

It is really deviated in a classic cleft lip nasal deformity way. There is absent maxillary and pre-maxillary bone on his left side because it is a left cleft, and then the caudal (front part) of the septum is deviated to the right – to the non-cleft side, and further back it is severely deviated to the left as you can see on the scan, in a very characteristic fashion for a cleft lip nasal deformity.


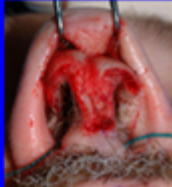
On the patient's pre-surgical front view picture, you can appreciate the deviation of the nasal bones to the right, to the non-cleft side. You can also appreciate the deviation of the middle nasal vault. There is a "concave left" deviation. There is also the characteristic tip deformity.

I did this rhinoplasty through an open rhinoplasty approach. And when you open his nose, you can also see the very characteristic problems with tip cartilages, where the cartilage on the cleft side, which is his left, (note to the Internet reader: as you look at this it is on your right), this lower lateral cartilage is posterior, inferior and laterally displaced (note to the Internet reader: this means down, in and back) compared to the right side. The medial crural part of the tip cartilage is short and the lateral crural part is long. So we are going to have to reposition those.

These diagrams of a classic cleft lip nasal deformity are taken with permission from the textbook Rhinoplasty Dissection manual, written by Dean Toriumi and me. While this is of course not always the case, you can compare this to the the actual, intraoperative photograph and get an idea that the classic cleft lip nasal deformity can be predictable.

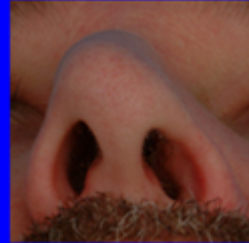

The following 2 slides detail the classic findings:

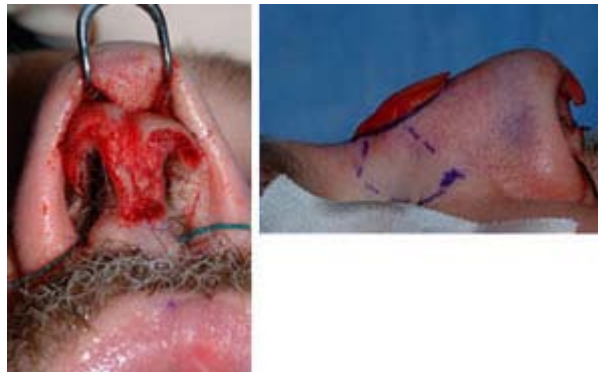
Cleft lip nasal deformity	
Tip	Columella
<ul style="list-style-type: none"> • Medial crus of LLC shorter on cleft side • Lateral crus of LLC longer on cleft side • Tip defining point on cleft side flat and laterally displaced 	<ul style="list-style-type: none"> • Short on cleft side • Columellar base directed to non-cleft side (unopposed orbicularis mm pull)
	

Cleft lip nasal deformity

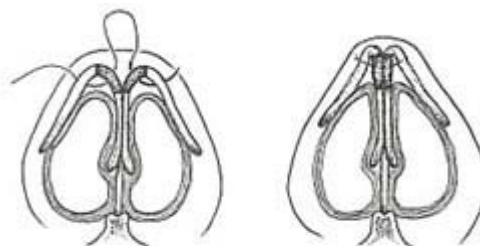
- Nostril – Horizontal orientation on cleft side
- Alar base – laterally, inferiorly, and posteriorly displaced (LIP)
- Nasal floor usually absent
- Septum – caudal deflection to non-cleft side
- Septum – Posterior deflection to cleft side



As you can see we also took down his bump and we are going to use that piece of material as a graft. So let me tell you what we did to fix this complex deviation.

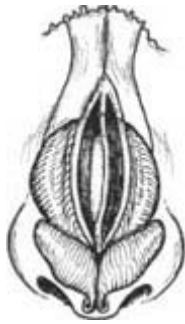

I straightened the septum for airway purposes, and also straightened the caudal septum to help straighten the nasal tip. (We'll talk about the techniques to straighten the caudal septum in a few minutes). I took down the nasal hump and performed bilateral medial and lateral osteotomies, straightening the upper nasal third. I returned to the nasal tip, where I placed plumping grafts to support the base of the nasal tip cartilages and fill out the nasolabial angle. I placed domal sutures on the right and left tip cartilage, but the left domal suture was placed using the "lateral crural steal" technique, thereby lengthening the medial crus at the expense of the lateral crus. Of course, the medial crus needed lengthening as it was too short. The lateral crural steal technique is illustrated in the diagram below. In this diagram it is applied to both tip cartilages, in this patient it was applied to only one tip cartilage, the left one.



This technique creates a deficiency of the lateral crus in these patients, and in this patient's case I used the excised nasal hump as a batten graft on the left side. This effectively reconstructed the left lateral crus of the left tip cartilage.

Finally, I addressed the middle nasal vault. After hump takedown, and after the other maneuvers I described, I carefully re-evaluated the middle nasal vault. There was some persisting deviation, and this was effectively treated with a left double layer spreader graft. The diagram below illustrates the concept that a unilateral spreader graft may be placed to address a twist of the middle vault.



It is important to emphasize that even though a classic cleft lip nasal deformity tends to be very similar from one to the other, the exact techniques that you use from patient to patient will surely differ in degree, and also the overall choice of techniques may differ due to a variety of factors, such as the severity of the deformity.

So to summarize, I think that the cleft lip nasal deformity is complicated - it includes all parts of the nose, upper, middle and lower thirds – but it is something that occurs in a repetitive way, it is sort of predictable, and so for a lecture like this on the severe or complex twisted nose, I feel this is a great starting point.

Chapter 5.


Rhinoplasty Lecture - Caudal Deflection

Let's take a look at another difficult problem, a patient with a severely deviated caudal septum.

Now, many times the front edge of the septum, which is called the caudal septum, is severely twisted. This can be a difficult problem to fix. There are numerous techniques in the literature that we are all familiar with that are available to the surgeon to fix this problem. The common one that we are aware of is the swinging door technique where this part of the septum is released and shifted over, and the surgeon tries to sew it into place in the middle. Sometimes we could also score or weaken the cartilage with a scalpel and also again try to sew it in place and then also sometimes when it is very severe, you can cut out that part and replace it with another piece of cartilage, a graft taken from further back in the septum usually. There are also other techniques that are described that are modifications of these, and I learned a technique that I would like to share with you called the doorstep technique. I learned it from Dr. Norm Pastorek, and he in turn learned it from one of his teachers. So this technique has been around for probably 70 years. And we actually wrote a paper about it in the medical literature, I would refer you to it for more detailed information.

Caudal Deflection

- Numerous techniques in the literature
 - Swinging door
 - Scoring & suture techniques
 - Excision and replacement
 - Others
- Doorstop technique of Pastorek



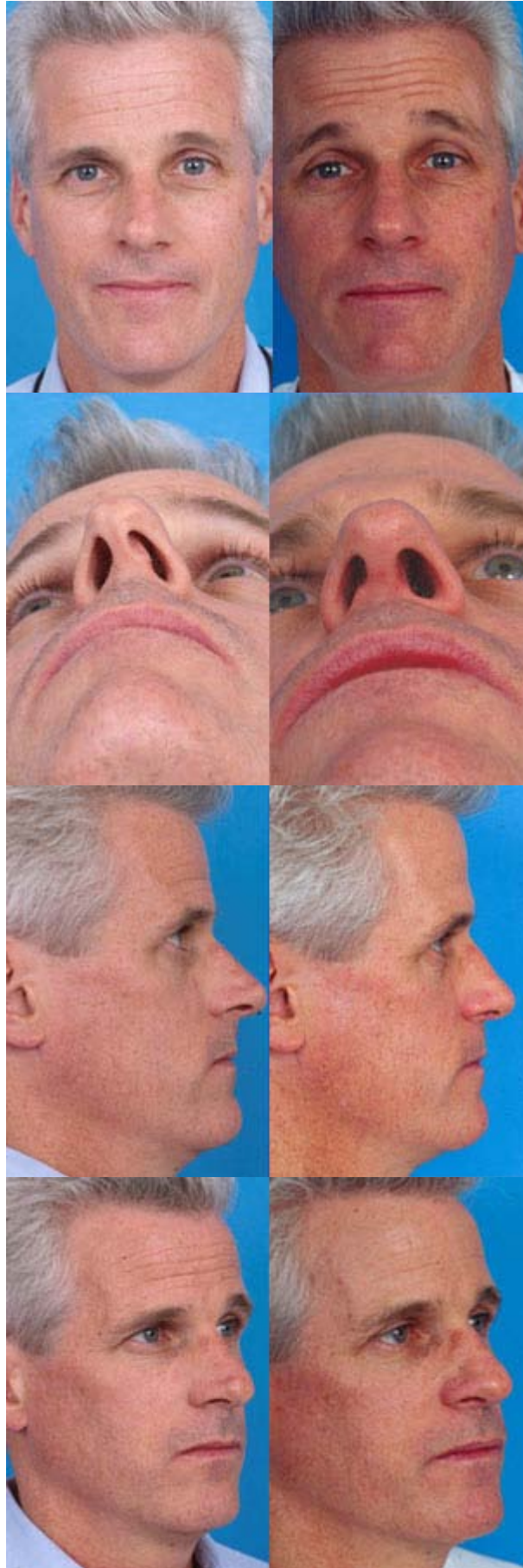SURGICAL TECHNIQUE

Treating the Caudal Septal Deflection

Norman J. Pastorek, MD; Daniel G. Becker, MD

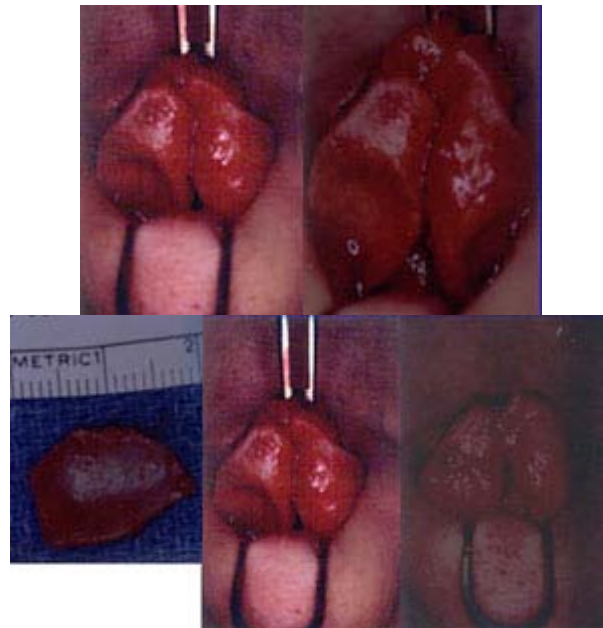
Caudal septal deflection can be a challenging nasal deformity. Although there are a number of maneuvers available to manage this functional and aesthetic abnormality, each approach is effective in only a limited number of cases. For over 25 years, the senior author (N.J.P.) has employed a "modified swinging door" technique for treatment of the deviated caudal septum. Using this technique, the septal cartilage along the maxillary crest is dissected free but is not excised. Instead, the caudal septum is flipped over the nasal spine, which acts as a "doorstop" and secures the caudal septum in a straighter position. This maneuver may be useful in the armamentarium of the surgeon managing this potentially difficult technical challenge.

Arch Facial Plast Surg. 2000;2:217-220

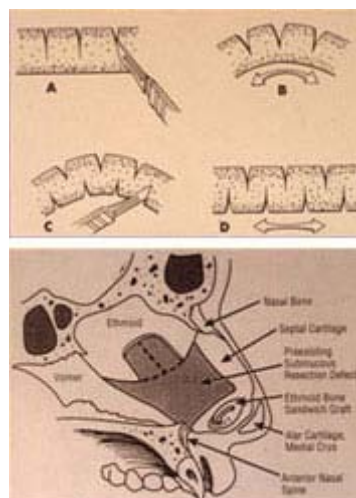


The way that we treat the severely deviated caudal septum, I will show you in a minute.

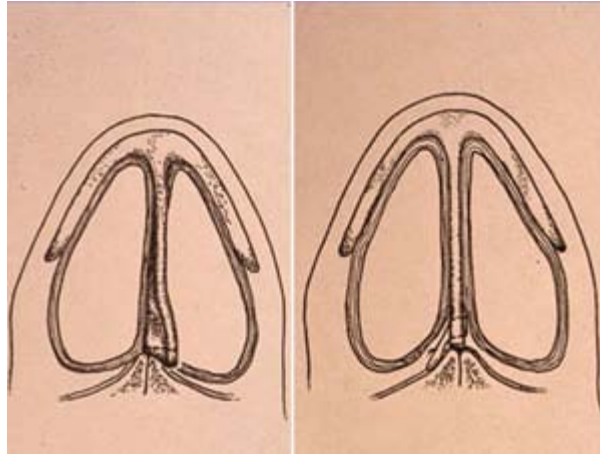
This patient also had a problem with his tip cartilages, where they were twisted and also the right one was very concave, it had a very deep bend in it. You can see this in the before and after pictures (above) where the septum was deviated to the left, and now it is back to the middle. And you can also see how a dent in the right side was fixed. What we did in this case, as you can see in these photos from during surgery, there was such a deep dent in that cartilage that we cut it out, that piece, and then flipped it over. So here you see the piece of cartilage cut out and then after you can see how the cartilage has been flipped and sewn back into place. That is an unusual cause of a deviation, but when we see that, it can be addressed rather nicely.



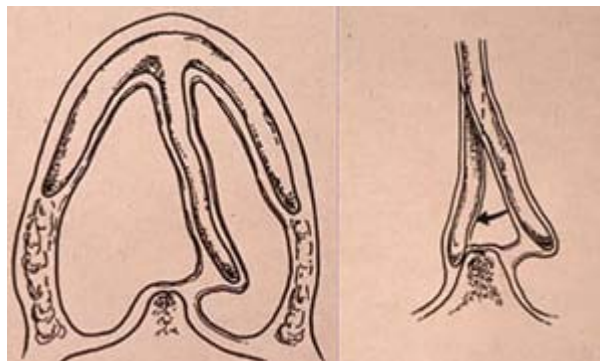
Now let's get back to the caudal septal deviation. This next slide shows the idea of scoring and bending the cartilage back into place, and also different kind of splinting grafts we can use to straighten the caudal septum, and those are all effective techniques in different patients. But, like almost all techniques, they do not work in all scenarios, and so you need to have many techniques in your armamentarium.



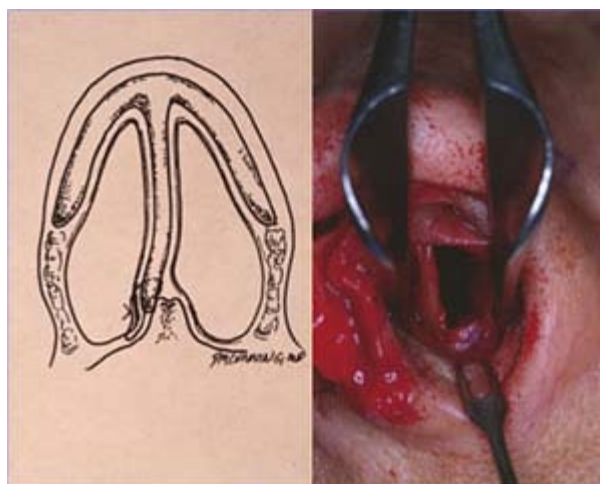
The swinging door technique, illustrated in this next slide, is a good technique that works in many cases. To do this technique, you cut off a piece of the bottom of the septum along the maxillary crest and you shift the remaining deviated caudal septum to the midline. Then, you rely on a suture to hold it in place.



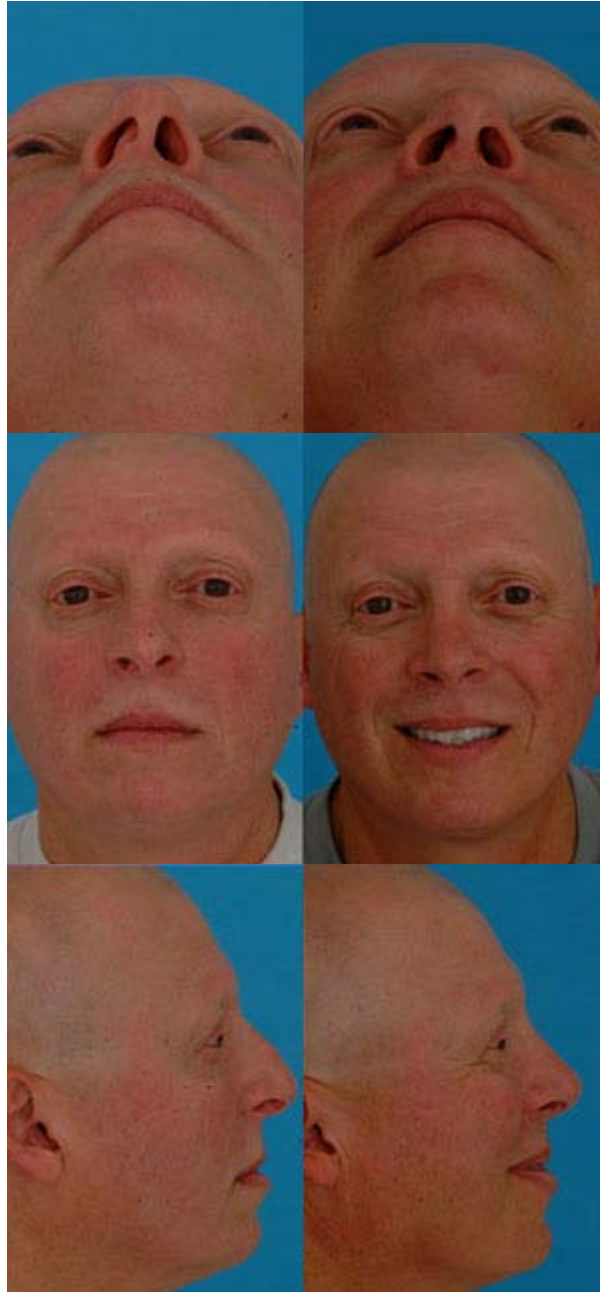
But the swinging door technique does not always work. It fails enough of the time that you should know about the doorstop technique. The doorstop technique keeps the length of the caudal septum, and as illustrated in this next slide, we release it and flip it over to the other side of the bone along the floor of the nose, the maxillary crest and nasal spine. The tension of the septum wants to hold it to the middle, and so by just flipping it over and using that little piece of bone as a doorstop, that will hold the caudal septum in place. You can put a suture there too if you feel additional security is necessary.



Here is a picture from surgery where there is a purple mark that I placed on the bone, and you can see how this septum is being held in place just like a door with a doorstop.



Here is another patient that I did the same procedure; it was, of course, on the opposite side, and it just worked so nicely in this patient as you can see from his smile is very happy. We also took down his bump and fixed the alar-columellar disproportion and some other things too.

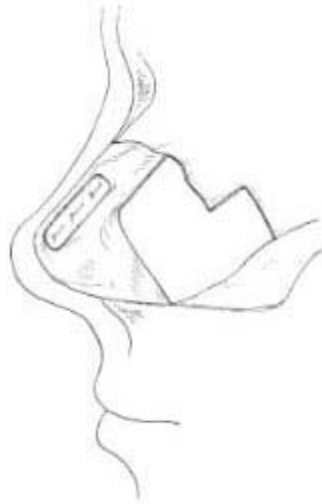

I would like to continue now by discussing severe twists of the middle nasal vault. We have talked about the twists of the upper portion, the bony part, and then of the tip. I have sort of saved the middle part for last because it can be easy sometimes, but it can also be the most challenging. In this next patient we straightened his nose by using unilateral spreader grafts – just as we described earlier in this lecture. The left side of this patient’s nose was straight enough, but the right side was just collapsed. Oftentimes a double layer spreader graft will suffice, but he is a big fellow. We actually used a 4 layer spreader graft, which is the most I have ever used.

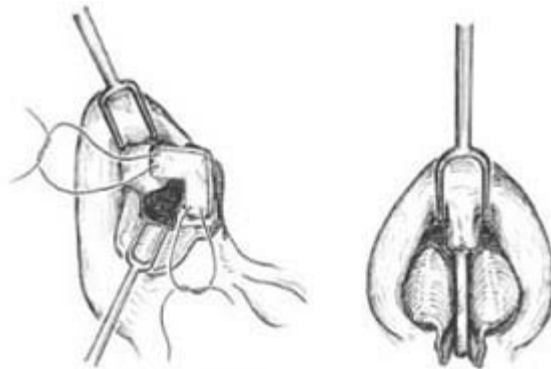
FOLLOWING PATIENT’S REQUEST, THIS PATIENT’S PHOTOGRAPHIC SLIDES NOT SHOWN ON INTERNET

A major reason that deviations of the middle vault can be a bit complicated to treat is that the middle part plays a support role, it is a support structure, the strut of the nose, and so you need to leave it strong so the nose in this section won't collapse. You cannot just score it to weaken it and allow it to straighten. You need to maintain its strength. Furthermore, this cartilage has memory, meaning that if you do not splint it in place it can also simply bend back.

Having said all of this, sometimes scoring the middle vault, with structural splinting with an ethmoid bone splinting graft, can be an effective technique. This is usually reserved for moderate deviations of this area. This technique is illustrated diagrammatically in the drawing below.

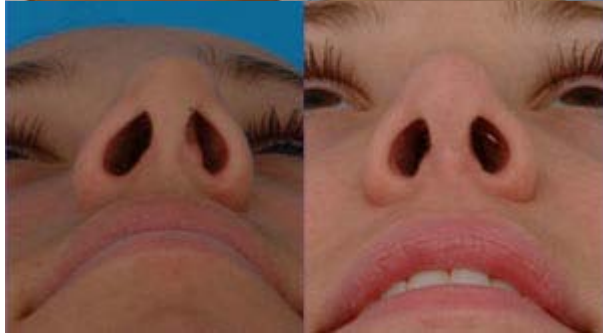
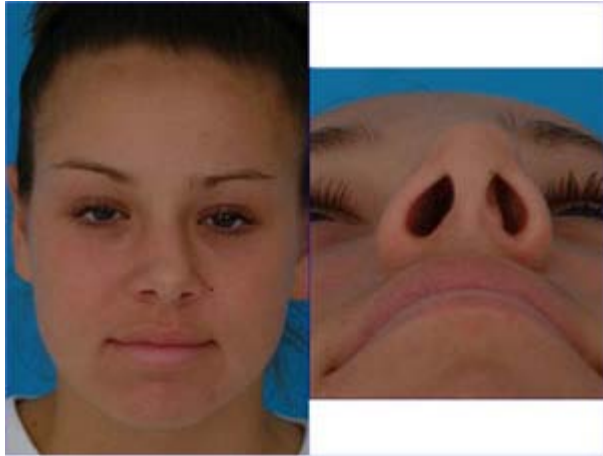
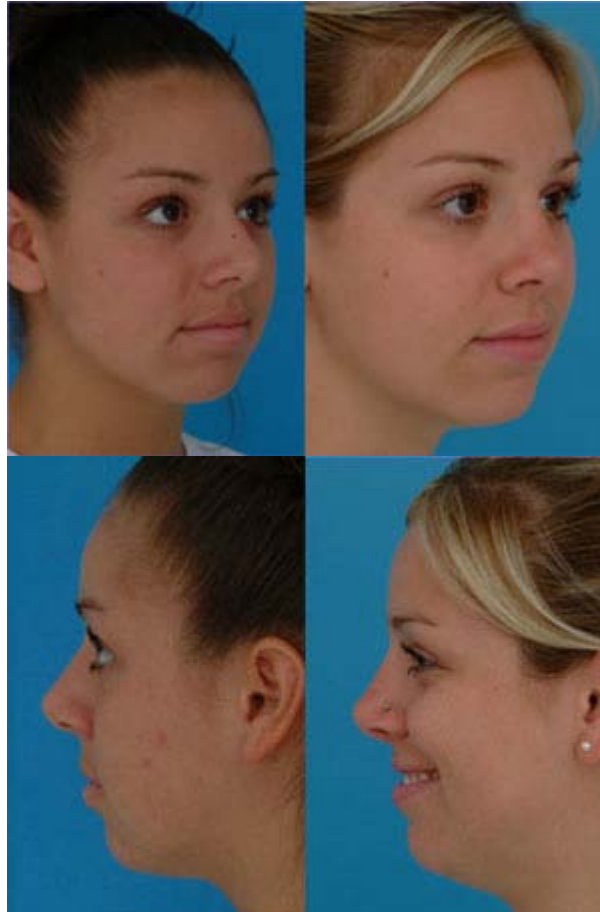And there are a number of other techniques that can be applied to the moderately deviated middle nasal vault. But the severely deviated middle nasal vault may require removal and replacement with a straight piece of cartilage. Often, the deviation extends beyond the middle vault to the caudal septum, and this can be even more complex. This diagram illustrates the concept of removing and replacing the entire cartilaginous middle vault and caudal septum! Of course, the guiding principle is to resect and replace only what is necessary to straighten the nose.



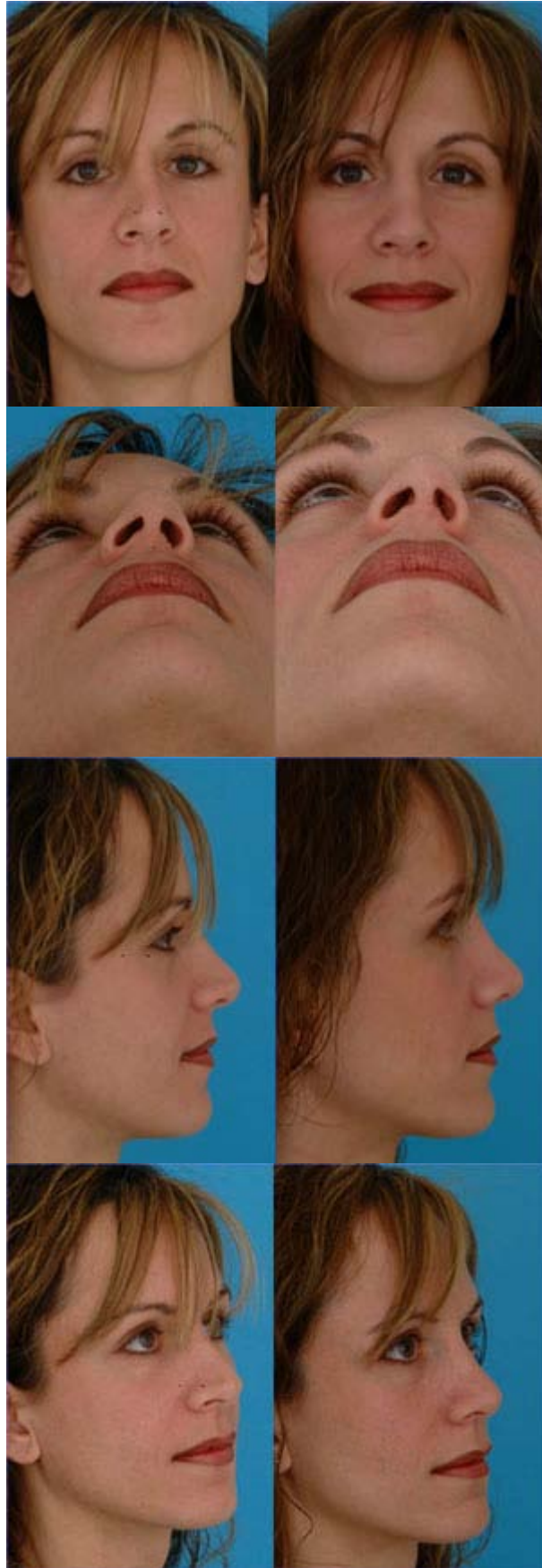In these severe and complex cases, this ends up being a very effective technique. I typically use the technique that has been described by Dr. Sam Most in the literature as anterior septal reconstruction. Essentially, the idea is that a portion of the cartilage must be preserved to attach the replacement graft to, and then the twisted part is cut out and replaced with a piece of straight cartilage.

Here is a patient, a young girl with a twisted nose in the middle, and often these are associated with a caudal septal deviation too, so that also needs to be fixed, but in her case I was able to simply straighten the caudal septum using the doorstep technique, and I cut out the cartilage of the middle portion and replaced it with septal cartilage harvested from posteriorly in her nose. And you can see one year later a wonderfully straight nose. She is certainly quite happy with it too, as you can see from the smile in her pictures.



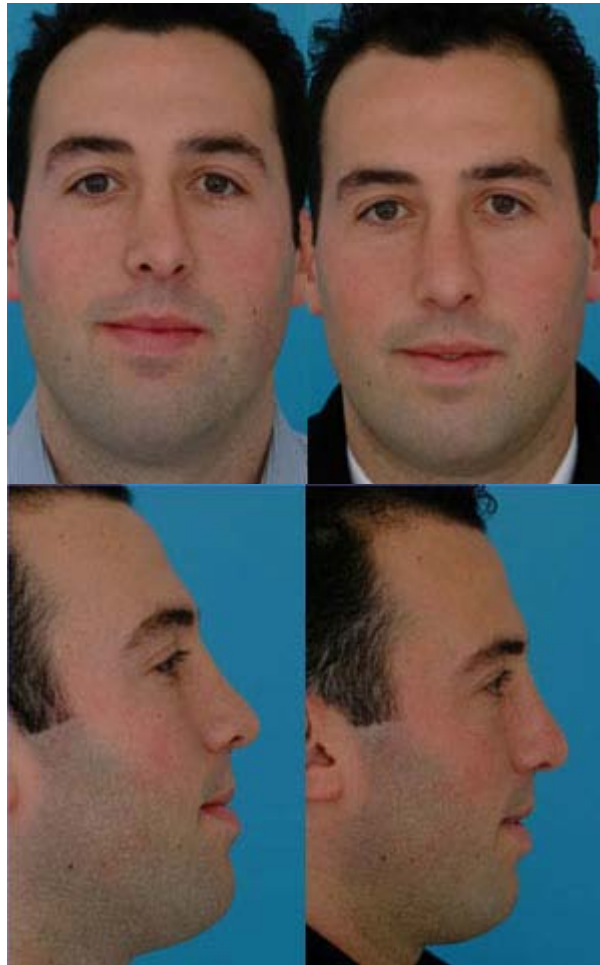

Here is another patient with the same sort of problem. She had 2 surgeries elsewhere, a primary surgery and then a revision, so the revision that I did was her third operation. She had had surgery elsewhere and then unfortunately it left her with a very severe twist. In her case, there was no available septal cartilage for replacement grafting, and so I removed the cartilage of the middle part of the nose and replaced it with new cartilage that in her case I took from behind her ear. And you can see her result, which is a significant improvement. There is still a little twist of it, if you look carefully, but she is quite pleased. Certainly, it is a significant improvement for her.

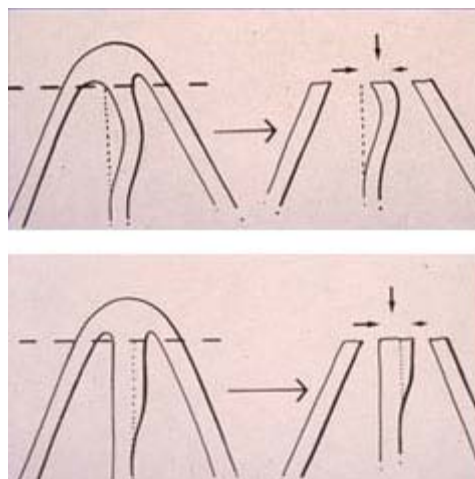


Here is yet another patient with the same sort of surgery and the same nice result. This is also a revision patient. There is a saying that your first chance is your best chance, and so usually we are able to do a little bit better job when we are the primary surgeon. If the patient has had

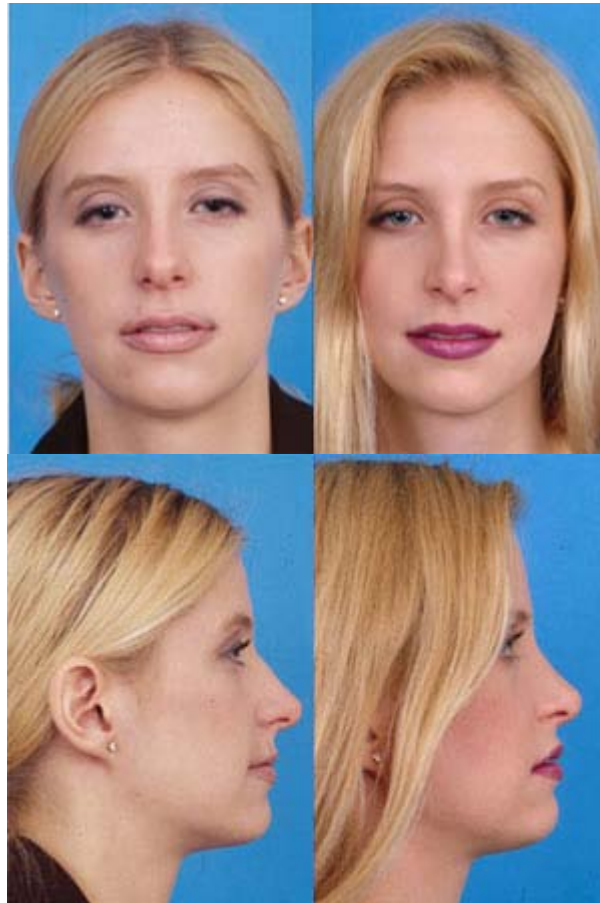previous surgery then that can make things a little bit more complicated, but as you can see, we are able to get a very, very nice result even in those cases.



So the last kind of deviation I will talk about is the iatrogenic deviation. Now when you take a patient who has a relatively straight nose and you are taking down a hump, there might be an underlying twist beneath. If you don't recognize it, then the patient can have a new twist to his or her nose. That can be because the septum underneath is thicker on one side, or it is shifted to one side. There can be danger hidden beneath the hump that you are taking down. As long as you recognize it, then it isn't a problem. If you miss it then it is something that you might have to go back and fix.



Here is a patient of mine who is one of my very, very happy patients, but as I look at her nose I can see in the after result that in the middle part of her nose on the right there is a little bit of a deviation that she did not have before. When you look at her side view picture and her other pictures you can see that she has a wonderful result, she is very, very happy. She did not want me to do anything further on this and was certainly very happy with her result. In other places you can see how her nose was twisted at the tip, and I have actually straightened it, but there was one problem that I did not see; this was earlier in my career and in any case I didn't see this. Of course, the point is that you definitely want to pay attention to all details, and make every effort to be sure that you do not miss a deviation that can be hidden underneath.



Well we could continue to talk about this sort of problem, the severely twisted nose, at great length, but my time is up and so I will say thank you. Thank you very much.